

Preliminary Study on The Effect of Combined Transurethral Plasma Bipolar Resection (TUPKBt) and Thulium Laser in The Treatment of Muscle-invasive Bladder Tumors

Hui Xiao, Bo Fang^{1,*}, Gang Qin

Department of Urology, Zhongjiang People's Hospital, Deyang 618100, China

*Corresponding email: 2016122537@jou.edu.cn

Abstract

Objective: Preliminary study on the effect of combined transurethral plasma bipolar resection (TUPKBt) and thulium laser in the healing of muscle-invasive bladder tumors. **Methods:** 68 patients with muscle-invasive bladder tumors who were healed in our hospital from July 2019 to March 2022 were opted and randomly divided into two clusters. The control cluster was healed with open radical cystectomy combined with lymphatic dissection, and the study cluster was healed with transurethral plasma bipolar resection (TUPKBt) combined with thulium laser therapy. To analyze the value of TUPKBt combined with thulium laser in the healing of muscle-invasive bladder tumors. **Results:** None notable variation in the operation time between the two clusters ($P>0.05$), but the intraoperative blood loss within the study cluster was bottom than that within the control cluster, and the indwelling catheter and hospital stay were shorter than those within the control cluster ($P<0.05$). None notable variation in immune indexes between the two clusters before operation ($P>0.05$). After operation, CD3+ and CD4+ within the study cluster were upper than those within the control cluster ($P<0.05$). None notable variation in inflammatory indexes between the two clusters before operation ($P>0.05$). The levels of C-reactive protein (CRP), tumor necrosis factor- α (TNF- α) and interleukin-6 (IL-6) in the cluster were bottom than those within the control cluster ($P<0.05$); None notable variation in the total remission rate between the two clusters ($P>0.05$); None notable variation in the life between the two clusters before surgery ($P>0.05$). The life mark was upper than that of the control cluster ($P<0.05$). **Conclusion:** In the healing of muscle-invasive bladder tumors, the application of TUPKBt combined with thulium laser therapy achieves ideal results, which can achieve similar efficacy to standard healing, and can reduce the impact on the body's immune function, reduce postoperative complications, and enhance life. It is worth promoting the application.

Keywords

Transurethral plasma bipolar resection, Thulium laser, Bladder tumors

Introduction

Muscle-invasive bladder tumor refers to cancer cells originating in the bladder mucosa and growing into the bladder, infiltrating the bladder muscle layer and above [1]. Painless gross hematuria is a typical symptom at the onset of the disease, and some show urinary tract irritation without hematuria, indicating a high degree of malignancy. Which can effectively enhance the survival rate of patients [2]. However, this method has great surgical damage and high postoperative complications, which is not conducive to the recovery of patients, and is greatly limited in the application of older patients with severe organ function [3]. Transurethral plasma bipolar resection (TUPKBt) is the main healing method for superficial bladder tumors, which has the advantages of

small damage, high safety and quick postoperative recovery [4]. In recent years, with the advancement of precise tumor healing, laser technology has been widely used in cystectomy, which can effectively seal tumor blood vessels and prevent cancer cells from spreading and metastasizing. It has a high application in the resection of various cancer tissues [5]. However, there are few studies related to muscle-invasive bladder tumors. In this paper, the effect of combined transurethral plasma bipolar resection (TUPKBt).

Materials and methods

General data

68 patients with muscle-invasive bladder tumors who

were healed in our hospital from July 2019 to March 2022 were opted and randomly divided into two clusters, 30 situations within the control cluster and 38 situations within the study cluster. within the control cluster, there were 24 males and 6 females, aged 51-85 years, mean (68.12±7.42) years old, tumor diameter 0.81-4.78cm, mean (2.73±0.21) cm; stage: T2 stage: 20 situations, T3 stage: 10 situations; 33 males and 7 females in the research cluster, aged 49-83 years, mean (67.63±7.06) years old, tumor diameter 0.70-4.81 cm, mean (2.74±0.23) cm; stage: T2 stage: 24 situations, T3 stage: 14 situations; the general data of the two clusters were comparable (P>0.05).

Inclusion criteria:

- (1) diagnosed by pathology and first episode.
- (2) in line with the indications for surgical healing.
- (3) the patients agreed to this study.

Exclusion criteria:

- (1) serious dysfunction of the heart and kidneys and other organs.
- (2) combined with other malignant tumors.
- (3) T4 stage tumors.

Methods

(1) Control cluster Open radical cystectomy, sterile towel laying, general anesthesia, supine position, 15-20 cm incision in the suprapubic area to the umbilicus, comprehensive exploration of the abdominal cavity, sequential pelvic lymph node dissection, cystectomy. After completion, a 10 cm ileal output tract was intercepted, and a new output tract was constructed. The ureter was trimmed as an oblique incision, inserted into the ileum, anastomosed and the output tract was fixed; in female patients, the uterine adnexa was removed at the same time.

(2) Study cluster TUPKbt combined with thulium laser, Holmium laser (Power suite 100w), USA, preoperative preparation is the same as the control cluster, plasma electrosurgery is inserted through the urethra to explore the tumour and ureteral orifice, thulium laser is used to perform circular vaporization cutting 1cm from the basal edge to remove the normal tissues around the tumour to the depth of the muscular layer, after completion, the tumour is removed using the “The tumour is then excised from the proximal end of the tumour along the basal direction to the distal end, and for stage T3 the whole bladder is excised [6-9].

A catheter was placed in the bladder and a dilute solution of Cetipix (60 mg of Cetipix + 60 ml of saline (0.9%) was injected into the bladder through the catheter and the bladder was changed once every 15 minutes and removed after 2 h. The catheter was removed once a week for 6 weeks.

Observation indicators

Contraction of surgical indicators: including surgery, indwelling catheter, hospital stay and intraoperative blood loss.

Contraction of immune and inflammatory indicators: immune indicators: CD3+, CD4+; inflammatory indicators: CRP, TNF- α , IL-6, determined by enzyme-linked immunosorbent assay.

Contraction of complications: Record all complications during the postoperative period in the hospital.

Efficacy Contraction: Complete remission (CR): The tumor disappeared and maintained for >1 month; Partial response (PR): The tumor diameter was shortened by >30% contrasted with before healing, with no new lesions and maintained for >1 month; Stable (SD): The tumor diameter was shortened by \leq 30% contrasted with that before healing, with no new lesions and maintained for >1 month; Progression (PD): The tumor increased or had new lesions, and the overall response rate was CR+PR.

Contraction of life: The 36-item Health Scale (SF-36) was used to evaluate, and a questionnaire survey was carried out in January after operation. 68 questionnaires were distributed and 68 were recovered. This evaluation opts 5 aspects, and each aspect is marked from 0 to 100 points, and the mark is positively correlated with life [10].

Statistical methods

The measurement data was represented by ($\bar{x} \pm s$), the t-test was used, the count data was represented by n (%), and the χ^2 test was used. P<0.05 indicated that the variation was notable.

Results

Contraction of surgical indicators

None notable variation in operation time between the two clusters (P>0.05), but the intraoperative blood loss within the study cluster was bottom than that within the control cluster, and the indwelling catheter and hospital stay were shorter than those within the control cluster (P<0.05) (Table 1).

Table 1. Contraction of surgical indicators ($\bar{x} \pm s$).

Cluster	Situations	Operating time (min)	Intraoperative bleeding (ml)	Duration of indwelling catheter (d)	Length of stay in hospital (d)
Control cluster	30	38.05±4.22	34.15±4.73	5.12±0.64	23.06±3.24
Study cluster	38	30.84±3.73	18.06±2.77	3.08±0.38	15.38±2.09
<i>T</i>	/	18.906	21.773	20.067	19.465
<i>P</i>	/	< 0.05	< 0.05	< 0.05	< 0.05

Contraction of immune indicators

None notable variation in immune indexes between the two clusters before operation ($P>0.05$), and the CD3+

and CD4+ within the study cluster were upper than those within the control cluster after operation ($P<0.05$) (Figure 1).

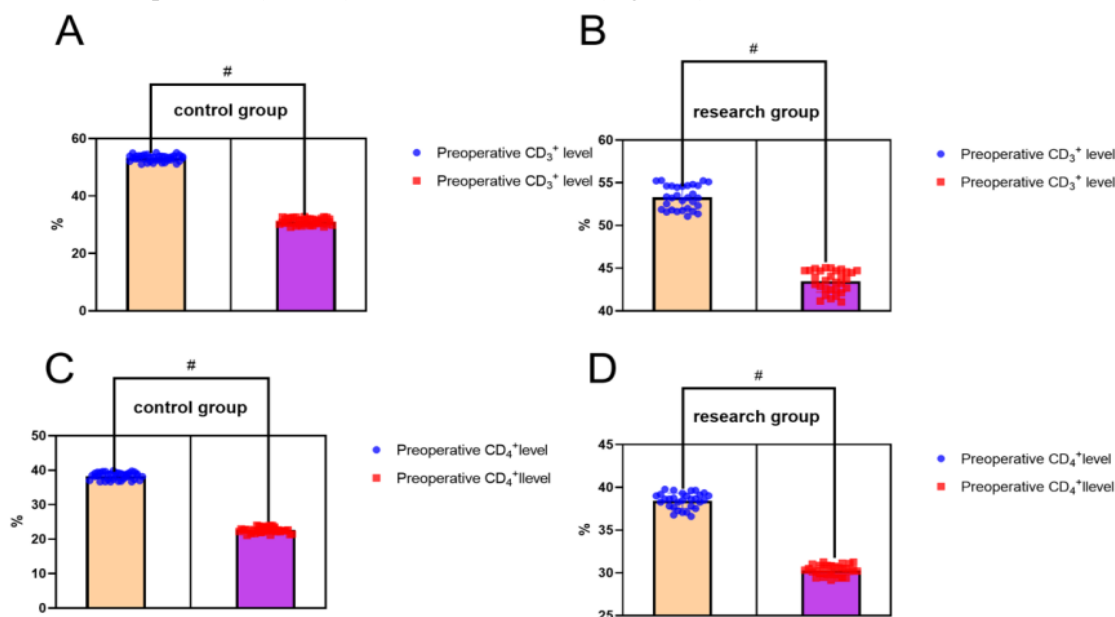


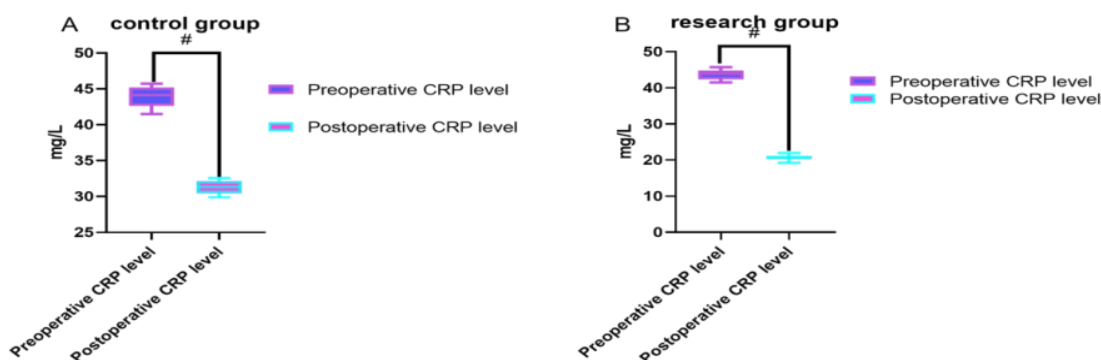
Figure 1. contraction of immune indexes of patients.

(Note: contraction of CD3+ and CD4+ before operation between the study cluster and control cluster, $P>0.05$, contraction between the study cluster and control cluster after operation, $P<0.05$, contraction between the two clusters before and after operation, $\#P<0.05$, indicating that None notable variation in preoperative immune indexes between the study cluster and control cluster, which was not statistically notable, and there was a

notable variation in postoperative immune indexes, which was statistically notable).

Contraction of inflammatory indicators

None notable variation in inflammatory indexes between the two clusters before surgery ($P>0.05$), and the levels of CRP, TNF- α and IL-6 within the study cluster were bottom than those within the control cluster after surgery ($P<0.05$) (Figure 2).



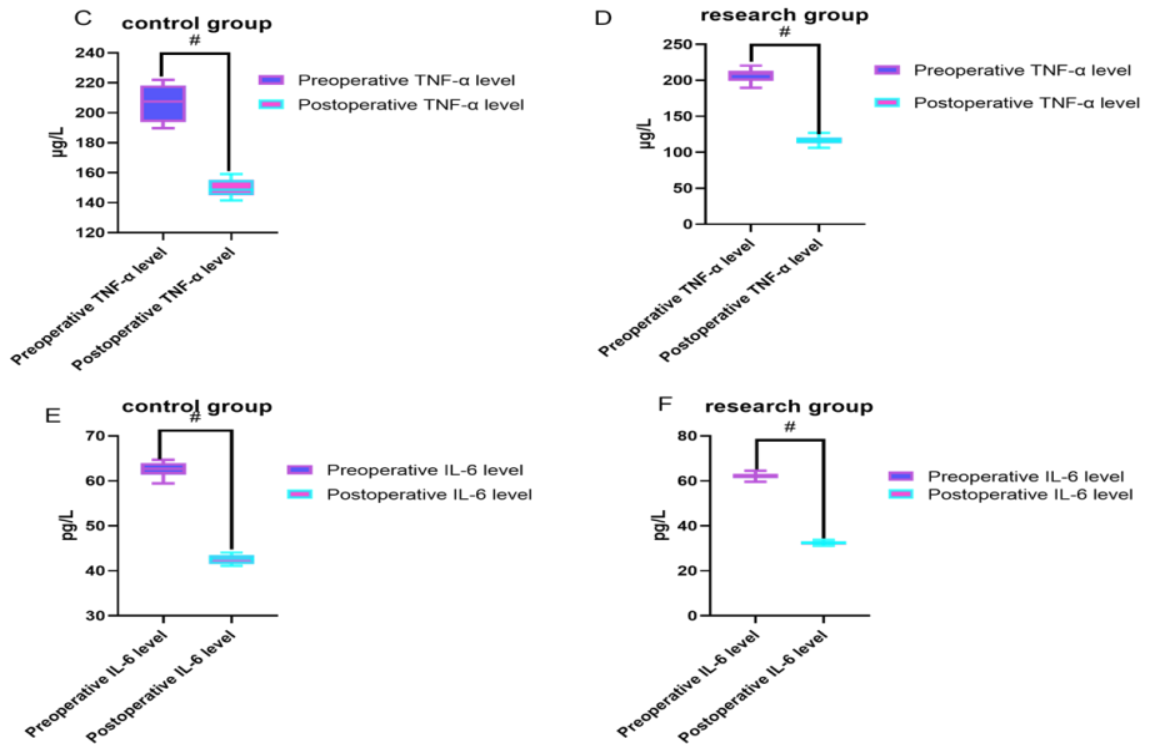


Figure 2. Contraction of immune indexes of patients.

(Note: Contraction of CRP, TNF- α , IL-6 before operation between the study cluster and control cluster, $P > 0.05$, contraction between the study cluster and control cluster after operation, $P < 0.05$, the contraction between the two clusters before operation and operation. The intra-cluster contraction, $P < 0.05$, indicated that None notable variation in the preoperative inflammatory

indexes between the study cluster and the control cluster, which was not statistically notable, and there was a notable variation in postoperative inflammatory indexes, which was statistically notable).

Contraction of complications

Complications within the study cluster was bottom than that within the control cluster ($P < 0.05$) (Figure 3).

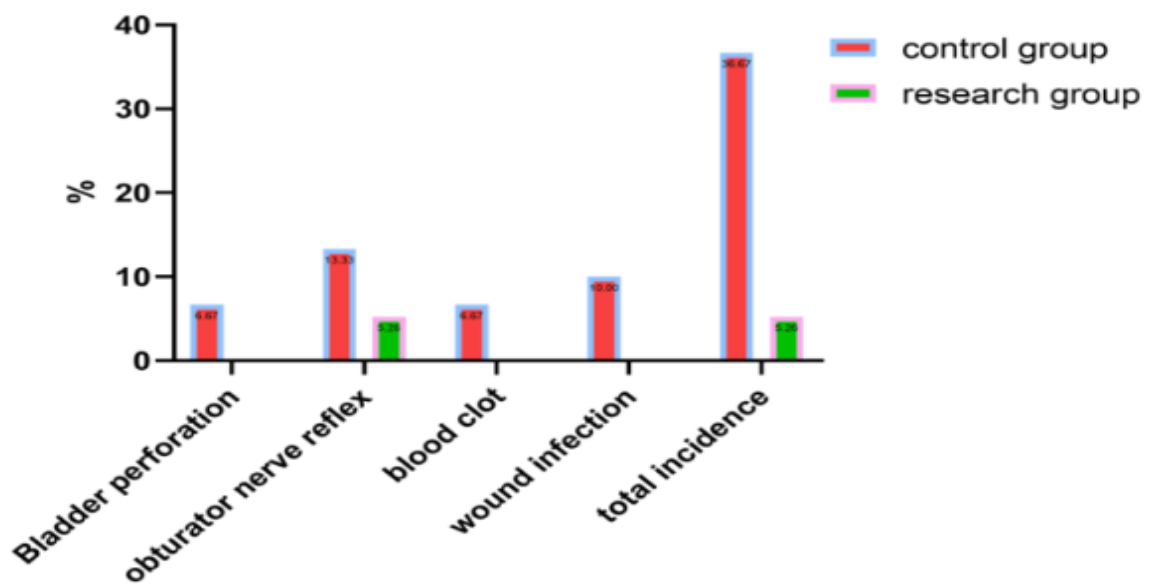


Figure 3. Contraction of complications in patients.

Note: The ratio of the total incidence of complications contrasted with the control cluster.

Contraction of curative effects

None notable variation in the overall remission rate between the two clusters ($P > 0.05$) (Figure 4).

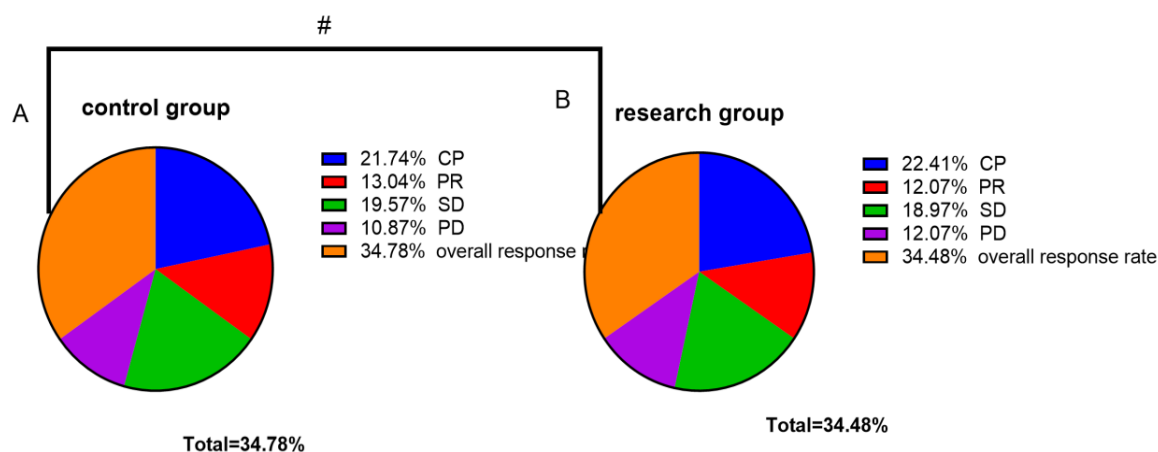


Figure 4. Contraction of curative effects of patients.

Note: contrasted with the total remission rate of the control cluster, $P > 0.05$, indicating that there is no notable variation in curative effect between the study cluster and the control cluster, and there is no statistical significance.

Contraction of life

None notable variation in the life between the two clusters before surgery ($P > 0.05$), and the postoperative life mark within the study cluster was higher than that within the control cluster ($P < 0.05$) (Table 2).

This indicates the intervention in the study group positively impacted patients' recovery and quality of life. These results suggest the approach may enable more effective postoperative management and improved long-term health outcomes.

Table 2. Contraction of life (points, $\bar{x} \pm s$).

Clusters	Time	Social functions	Somatic functions	Character Functions	Cognitive functions	Emotional function
Control cluster	Pre-op	43.06±4.84	40.45±3.57	42.84±4.72	44.78±3.15	39.09±3.17
	Postoperative#	50.35±4.80	44.47±3.31	49.95±3.81	50.45±3.52	44.38±3.56
Study cluster	Pre-op	42.97±4.63	40.61±4.33	42.79±4.85	44.95±4.20	39.11±4.25
	Post-operative ##	61.35±4.86	51.08±3.86	58.95±5.14	59.56±4.84	58.61±4.83

Note: the contraction between the control cluster and the research cluster within the two clusters, $\#P < 0.05$, there is a notable variation in the life within the cluster, with statistical significance; the contraction between the two clusters, $\#P < 0.05$, It indicated that there was a notable variation in the life between the two clusters after surgery, with statistical significance.

Discussion

At present, there is no clear pathogenesis of bladder tumor in the medical community, but studies have confirmed that its findings are related to smoking, chemical stimulation, chronic infection and other factors. According to relevant data, the incidence of bladder tumors has continued to rise in recent years, and it is more common in middle-aged and elderly men. Benign tumors can be cured after effective healing, but malignant tumors have a poor prognosis. In the past, in

the healing of muscle-invasive bladder tumors, open radical cystectomy combined with lymphatic dissection was the standard healing plan, which can effectively remove tumor tissue and reduce tumor recurrence and metastasis. However, this surgical method requires a large incision in the abdomen of the patient, which has the disadvantages of large trauma, large intraoperative loss, high postoperative complications, and relatively slow postoperative recovery, which can no longer meet the medical needs of modern society.

The emergence of TUPKBt provides a new direction for the healing of bladder tumors, but the obturator nerve reflex is easily triggered during the operation. With the development of laser technology, the emergence of thulium laser also provides a new method for preventing or reducing the obturator nerve reflex. Therefore, in this study, 68 patients with muscle-invasive bladder tumors were opted and healed with TUPKBt combined with thulium laser and combined with the healing contrasted with the gold standard surgical methods. It was found that None notable variation in the effects of the two methods, suggesting that TUPKBt combined with thulium laser has an upper application value in the healing of muscle-invasive bladder tumors. The thulium laser is a solid-state pulsed laser with obvious ablation effect. Several studies have found that based on TUPKBt healing, combined with thulium laser resection of tumors can effectively avoid the occurrence of the obturator nerve reflex. This study found that, contrasted with standard healing, TUPKBt combined with thulium laser combined with muscle-invasive bladder tumor reduced the incidence of complications, especially the obturator nerve reflex. The reason may be related to the characteristics of thulium laser itself. The wavelength of thulium laser is 2 μ m, which has extremely high cutting efficiency for tissue, and can achieve fine cutting of tissue. The thermal damage to the tissue is small, and the hemostatic effect is obvious. It can quickly close the lymphatic vessels and blood vessels around the tumor pedicle, thereby preventing the tumor cells from flowing back into the blood, which can effectively prevent the spread of tumor cells and distant metastasis. At the same time, contrasted with conventional resection, it can effectively reduce the residual tumor tissue and reduce postoperative recurrence by completely removing the tumor at the base of the tumor.

Surgery is an exogenous stimulus that affects the body's immunity and the metabolism of inflammatory factors. Among them, T cell subsets can reflect the state of immune regulation in the body, usually including CD3+ and CD4+, which are in a dynamic balance under normal conditions. Status. When the body is traumatized, the immune function is damaged, resulting in a decrease in CD3+ and CD4+, so it can reflect the degree of adverse effects of surgery on the body's immunity. Some studies have found that surgical trauma can cause an increase in

inflammatory factors, and the elevated levels are positively correlated with the degree of trauma, among which TNF- α , IL-6, and IL-8 are key pro-inflammatory factors. TNF- α is a factor that triggers acute phase response.

When nflammatory pathological damage is caused by surgery, TNF- α can be released in large quantities, and IL-6 and IL-8 can be induced to mediate the occurrence of local inflammation, which affects postoperative recovery. This study found that TUPKBt combined with thulium laser combined with muscle-invasive bladder tumor had less impact on the patient's immune function and analyzed that it may be related to less trauma to the body, which can not only reduce the occurrence of postoperative complications, and it can be beneficial to the recovery of patients and enhance the life after surgery. Contrasted with open radical cystectomy combined with lymphatic dissection, less postoperative impact on normal life, and upper patient tolerance. However, it should be noted that after surgery, chemotherapy should be completed in accordance with the doctor's instructions, and regular review should be carried out. At the same time, this kind of operation has high requirements for equipment, and many grass-roots hospitals cannot carry it out, resulting in limited practical application. Therefore, in the actual healing. There are still many deficiencies. Due to the limitation of follow-up time, this study did not compare the survival rate and recurrence rate of patients within 3 years and 5 years. to enhance the accuracy of the experimental data.

Conclusion

The application of TUPKBt combined with thulium laser therapy has achieved ideal results, and the therapeutic effect can be like the standard healing of open radical cystectomy with lymphatic dissection. It causes less trauma to the patient, reduces the impact on the immune function of the body, reduces complications and facilitates postoperative rehabilitation, and does not require reconstruction of the output tract after surgery, and has an upper life, which is worthy of popularization and application.

Funding

This work was not supported by any funds.

Acknowledgements

The authors would like to show sincere thanks to those

techniques who have contributed to this research.

Conflicts of Interest

The authors declare no conflict of interest.

References

- [1] Freitas, N. R., Vieira, P. M., Lima, E., Lima, C. S. (2018) Automatic T1 bladder tumor detection by using wavelet analysis in cystoscopy images. *Physics in Medicine & Biology*, 63(3), 035031.
- [2] Hamad, J., McCloskey, H., Milowsky, M. I., Royce, T., Smith, A. (2020) Bladder preservation in muscle-invasive bladder cancer: a comprehensive review. *International Braz J Urol*, 46(2), 169-184.
- [3] Defidio, L., Antonucci, M., Castellani, D., Civitella, A., Esperto, F., Scarpa, R. M. (2021) Transurethral resection of bladder tumor: electrosurgical and laser. *Journal of Endourology*, 35(S2), S-46.
- [4] Herr, H. (2021) Improving the quality of transurethral resection of bladder tumor: urologist, audit thyself. *European Urology Oncology*, 4(1), 20-21.
- [5] Bogdan, G. (2021) Editorial comment on: "primary complete transurethral resection of bladder tumor using photodynamic diagnosis for high-risk nonmuscle invasive bladder cancer: Is a restaging photodynamic transurethral resection really necessary?" by Tadrict et al. *Journal of Endourology*, 35(7).
- [6] Martins, F. E., Bernal, J., Tryfonyuk, L., Holm, H. V. (2024) Artificial urinary sphincter and stricture disease: surgical principles in management. *Translational Andrology and Urology*, 13(8), 1717.
- [7] Hamza, A., Guo, C. C. (2020) Perivascular epithelioid cell tumor of the urinary bladder: a systematic review. *International Journal of Surgical Pathology*, 28(4), 393-400.
- [8] Ayati, M., Amini, E., Damavand, R. S., Nowroozi, M. R., Soleimani, M., Ranjbar, E., Nowroozi, A. (2019) Second transurethral resection of bladder tumor: is it necessary in all T1 and/or high-grade tumors. *Urology Journal*, 16(2), 152-156.
- [9] Haga, N., Tsubouchi, K., Maruta, H., Koguchi, T., Hoshi, S., Ogawa, S., Kojima, Y. (2020) Increase in circulating tumor cells in invasive bladder cancer after transurethral resection of bladder tumor. *Anticancer Research*, 40(8), 4299-4307.
- [10] Gondran-Tellier, B., Abdallah, R., Sichez, P. C., Akiki, A., Toledano, H., Gaillet, S., Baboudjian, M. (2021) Continuous saline bladder irrigation after blue light transurethral resection of bladder tumor increases recurrence-free survival in low-to intermediate-risk non-muscle invasive bladder cancer. *Progres en Urologie*, 31(6), 316-323.